

# CASE REPORT

**Carcinoma of the descending colon with infiltration of the peritoneum, infiltration into the bladder and metastases of the liver in a 53 years old male patient**

Prof. Dr. med. Hans U. Baer,  
MD, Associate Professor of Surgery  
Baermed, Center for Abdominal Surgery  
Witellikerstrasse 40  
CH-8032 Zurich  
Switzerland

[hans.baer@baermed.ch](mailto:hans.baer@baermed.ch)  
[www.baermed.ch](http://www.baermed.ch)

Phone +41 44 387 30 70  
Fax +41 44 387 30 90

Dr. Barlian Sutedja, Sp.B  
President Director  
Gading Pluit Hospital  
Jl. Boulevard Timur Raya, Kelapa Gading  
Jakarta 14250  
Indonesia

[dr.barlian@pluit-hospital.com](mailto:dr.barlian@pluit-hospital.com)  
[www.gadingpluit-hospital.com](http://www.gadingpluit-hospital.com)

Phone (62-21) 4521001  
Fax (62-21) 4520578

## CASE HISTORY

This 53 years old male patient presented with a protrusion in the hypogastric abdominal area. This protrusion increased in diameter since one year. When passing urine mucosal content was found. Weight loss of 17kg over one year.

## CLINICAL FINDINGS

- Blood pressure 120/80 mmHg.
- Heart frequency 100/min
- Cardio pulmonary within the standard range
- Protrusion of 15cm in diameter in the upper abdomen

## MSCT SCAN OF THE ABDOMEN

Sigmoid with intraluminal mass infiltrating the colonic wall, the adjacent anterior peritoneum and the wall of the urinary bladder. Tumor infiltrating the rectus muscle and the retroperitoneum from the height of L3. Ventral tumor mass infiltrating the abdominal wall from the umbilicus to the pelvis.

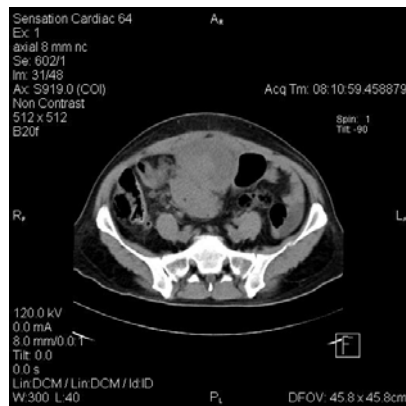

Fig. 1: CT scan: abdominal mass infiltrating into the anterior abdominal wall

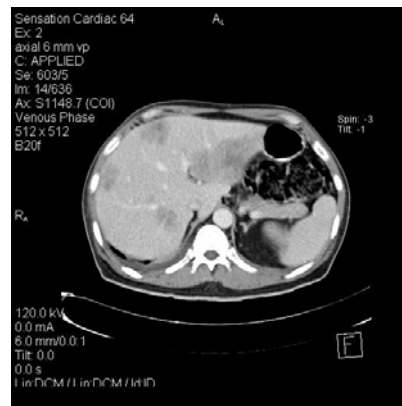

Fig. 2: CT scan: multiple lesions in all segments of the liver

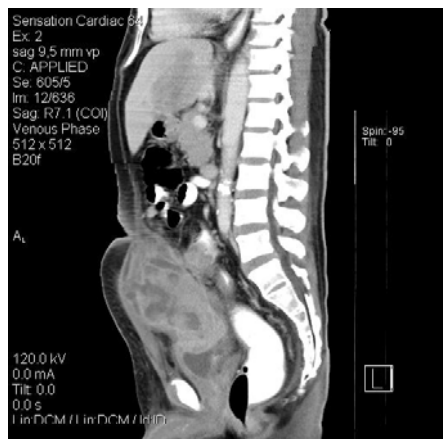

Fig. 3: CT scan: intraabdominal mass infiltrating into the roof of the urinary bladder

## COLONOSCOPY

Malignant mass 19 cm above the anus obstructing the entire lumen of the sigmoid.

## HISTOLOGICAL FINDING

Adenocarcinoma of the sigmoid. The histological staging was impossible because of superficial mucosal biopsy.

## INDICATION

Obstructing carcinoma of the descending colon and sigmoid with infiltration into the anterior abdominal wall threatening to rupture. Tumour infiltration into the roof of the urinary bladder. Multiple liver metastases.

## OPERATION

Resection of the anterior abdominal wall  
Resection of the Sigmoid and reanastomosis of the colon.  
Resection of 50% of the urinary bladder.  
Resection of Segment II and III of the liver.  
Intraoperative cryotherapy of the liver metastases in the right liver

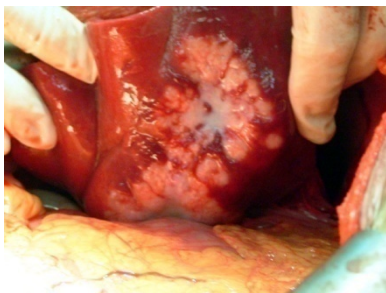

Fig. 4: Metastases of Segment II and III of the liver

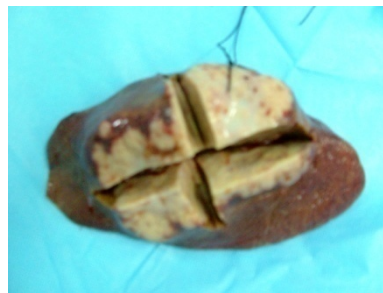

Fig. 5: resected specimen of the Segment II and III left Liver

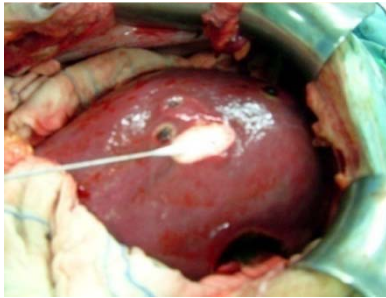


Fig. 6: intraoperativ cryo therapy of the metastases of the right liver. White area is frozen superficial liver tissue. Cryotube with frozen area of the liver.

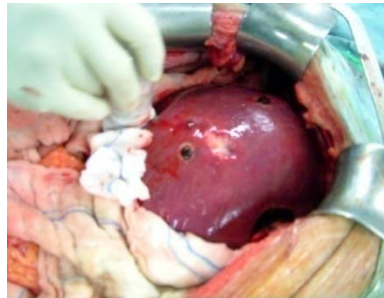


Fig. 7: Condition after cryo therapy. Liver surface with coagulation spots.

## HISTOLOGY

Adenocarcinoma of the descending colon (pT4 Nx M1) DUKES D

## POSTOPERATIVE DIAGNOSIS

- Adenocarcinoma of the descending colon with multiple metastases of the liver
- Tumour infiltration into the anterior abdominal wall
- Tumour infiltration into the roof of the urinary bladder

## CLINICAL COURSE

Folfox Chemotherapy every two weeks : Eloxatin 120 mg, Rescuvolin 300 mg, 5 FU : 600 + 875 mg.

The general condition of the patient is well. No clinical symptoms.

## PROBLEMS

No postoperative problems.

## DISCUSSION

The question whether a patient should be resected and treated with combined ablative methods for metastizing colorectal tumours remains controversial. The tumour infiltrating the abdominal wall threatening to break open, the nearly complete obstruction of the sigmoid as well as the problems with the bladder made a palliative approach inevitable. Postoperative chemotherapy and close follow up with possibly later percutaneous repetitive cryotherapy remains a possibility to treat this patient.